
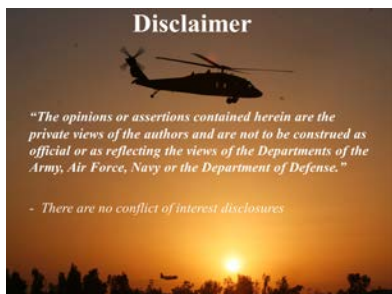







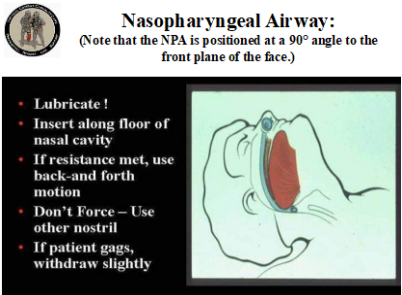
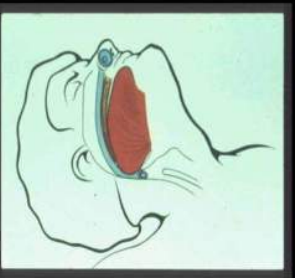
















<p>1.</p>	<p>Tactical Combat Casualty Care for Medical Personnel August 2018 (Based on TCCC-MP Guidelines 180801)</p>  <p>Tactical Field Care 1c Airway</p>	<p>Tactical Combat Casualty Care for Medical Personnel August 2018 (Based on TCCC-MP Guidelines 180001)</p> <p>Tactical Field Care 1c Airway</p>	<p>Now let's discuss management of the airway.</p>
<p>2.</p>		<p>Disclaimer</p> <p><i>“The opinions or assertions contained herein are the private views of the authors and are not to be construed as official or as reflecting the views of the Departments of the Army, Air Force, Navy or the Department of Defense.”</i></p> <p>- <i>There are no conflict of interest disclosures</i></p>	<p>Read the disclaimer.</p>
<p>3.</p>	 <p>LEARNING OBJECTIVES</p> <p><u>Terminal Learning Objective</u></p> <ul style="list-style-type: none"> • Perform Airway Management in Tactical Field Care. <p><u>Enabling Learning Objectives</u></p> <ul style="list-style-type: none"> • Describe the progressive strategies, indications, and limitations of airway management techniques in tactical field care. • Describe the spinal precaution considerations for penetrating vs blunt trauma. 	<p>LEARNING OBJECTIVES</p> <p><u>Terminal Learning Objective</u></p> <ul style="list-style-type: none"> • Perform Airway Management in Tactical Field Care. <p><u>Enabling Learning Objectives</u></p> <ul style="list-style-type: none"> • Describe the progressive strategies, indications, and limitations of airway management techniques in tactical field care. • Describe the spinal precaution considerations for penetrating vs blunt trauma. 	<p>Read the text.</p>




<p>4.</p>	 <p>LEARNING OBJECTIVES</p> <p><u>Enabling Learning Objectives</u></p> <ul style="list-style-type: none"> • Describe the importance of the sit-up and lean-forward maneuver to manage airway trauma in conscious casualties • Demonstrate opening the airway with the chin-lift/jaw-thrust maneuver. • Demonstrate the insertion of a nasopharyngeal airway. • Demonstrate the insertion of an extraglottic airway. 	<p>LEARNING OBJECTIVES</p> <p><u>Enabling Learning Objectives</u></p> <ul style="list-style-type: none"> • Describe the importance of the sit-up and lean-forward maneuver to manage airway trauma in conscious casualties • Demonstrate opening the airway with the chin-lift/jaw-thrust maneuver. • Demonstrate the insertion of a nasopharyngeal airway. • Demonstrate the insertion of an extraglottic airway. 	<p>Read the text.</p>
<p>5.</p>	 <p>LEARNING OBJECTIVES</p> <p><u>Enabling Learning Objectives</u></p> <ul style="list-style-type: none"> • Identify the indications for cricothyroidotomy and the preferred methods. • Identify the correct site for cricothyroidotomy. • Demonstrate the recommended procedure for a surgical cricothyroidotomy. • Identify the importance and application of pulse oximetry monitoring in TFC airway management. 	<p>LEARNING OBJECTIVES</p> <p><u>Enabling Learning Objectives</u></p> <ul style="list-style-type: none"> • Identify the indications for cricothyroidotomy and the preferred methods. • Identify the correct site for cricothyroidotomy. • Demonstrate the recommended procedure for a surgical cricothyroidotomy. • Identify the importance and application of pulse oximetry monitoring in TFC airway management. 	<p>Read the text.</p>
<p>6.</p>	 <p>Tactical Field Care Guidelines</p> <p>4. Airway Management</p> <p>a. Conscious casualty with no airway problem identified</p> <p>- No airway intervention required</p> <p><i>* New material in red text</i></p>	<p>Tactical Field Care Guidelines</p> <p>4. Airway Management</p> <p>a. Conscious casualty with no airway problem identified</p> <p>- No airway intervention required</p> <p><i>* New material in red text</i></p>	<p>Read the guideline.</p>
<p>7.</p>	 <p>Tactical Field Care Guidelines</p> <p>4. Airway Management</p> <p>b. Unconscious casualty without airway obstruction:</p> <ul style="list-style-type: none"> - Place casualty in the recovery position - Chin lift or jaw thrust maneuver or - Nasopharyngeal airway or - Extraglottic airway <p><i>* New material in red text</i></p>	<p>Tactical Field Care Guidelines</p> <p>4. Airway Management</p> <p>b. Unconscious casualty without airway obstruction:</p> <ul style="list-style-type: none"> - Place casualty in the recovery position - Chin lift or jaw thrust maneuver or - Nasopharyngeal airway or - Extraglottic airway <p><i>* New material in red text</i></p>	<p>Read the guideline.</p>






<p>8.</p>	 <p>Chin Lift and Jaw Thrust Maneuvers</p>	<p>Chin Lift and Jaw Thrust Maneuvers</p>	<p>Click on the photo to play the video.</p>
<p>9.</p>	 <p>Nasopharyngeal Airway</p> <ul style="list-style-type: none"> • The “Nose Hose,” “Nasal Trumpet,” “NPA” • Excellent success in Afghanistan and Iraq • Well tolerated by the conscious patient • Lube before inserting • Insert at 90-degree angle to the face, NOT along the axis of the external nose • Tape it in • Don’t use an oropharyngeal airway (‘J’ Tube) <ul style="list-style-type: none"> – Will cause conscious casualties to gag – Easily dislodged 	<p>Nasopharyngeal Airway</p> <ul style="list-style-type: none"> • The “Nose Hose,” “Nasal Trumpet,” “NPA” • Excellent success in Afghanistan and Iraq • Well tolerated by the conscious patient • Lube before inserting • Insert at 90-degree angle to the face, NOT along the axis of the external nose • Tape it in • Don’t use an oropharyngeal airway (‘J’ Tube) <ul style="list-style-type: none"> – Will cause conscious casualties to gag – Easily dislodged 	<p>The oropharyngeal airway is more easily dislodged and more likely to cause gagging in a conscious casualty.</p> <p>The NPA is better tolerated by a conscious patient</p>
<p>10.</p>	 <p>Nasopharyngeal Airway: (Note that the NPA is positioned at a 90° angle to the front plane of the face.)</p> <ul style="list-style-type: none"> • Lubricate! • Insert along floor of nasal cavity • If resistance met, use back-and forth motion • Don’t Force – Use other nostril • If patient gags, withdraw slightly 	<p>Nasopharyngeal Airway: (Note that the NPA is positioned at a 90° angle to the front plane of the face.)</p>  <ul style="list-style-type: none"> • Lubricate! • Insert along floor of nasal cavity • If resistance met, use back-and forth motion • Don’t Force – Use other nostril • If patient gags, withdraw slightly 	<p>Lubricate! Insert gently with a rotary or back and forth motion. Don’t start a big nosebleed. Some people have a deviated nasal septum – try the other nostril if the NPA doesn’t go in the first side you try.</p>

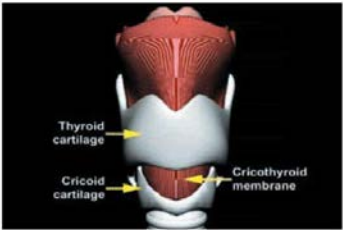
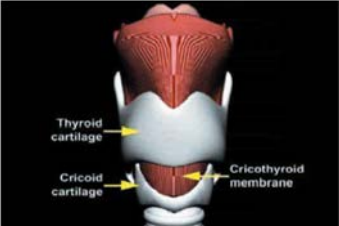
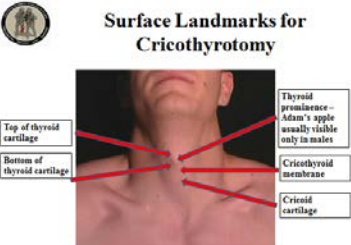
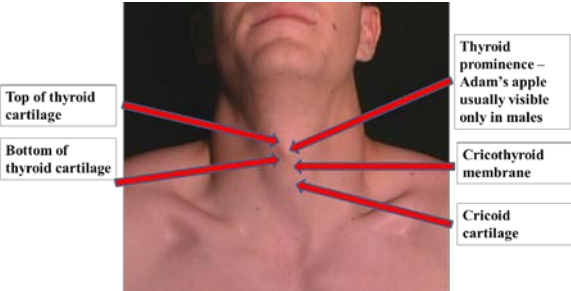
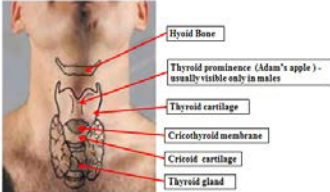
<p>11.</p>	<p> Nasopharyngeal Airway</p>  <p>What's wrong with this NPA insertion?</p>	<p>Nasopharyngeal Airway</p> <p>What's wrong with this NPA insertion?</p>	<p>This nasopharyngeal airway is being inserted towards the brain and may end up there if there are craniofacial or basilar skull fractures! The correct angle for insertion is 90 degrees to the frontal plane of the face - NOT along the long axis of the nose.</p>
<p>12.</p>	<p> Nasopharyngeal Airway Insertion</p> 	<p>Nasopharyngeal Airway Insertion</p>	<p>The correct insertion angle for the NPA will cause it to track along the base of the nasal cavity and will not upward toward the brain.</p> <p>Click on the photo to play the video.</p>
<p>13.</p>	<p> Recovery Position</p> <p>Place unconscious casualties in the recovery position after the airway has been opened.</p>  <p>Figure 5-1</p>	<p>Recovery Position</p> <p>Place unconscious casualties in the recovery position after the airway has been opened.</p>	<p>Recovery position helps to protect against vomiting and aspiration. Note that C-spine stabilization is not required with penetrating head and neck trauma.</p>

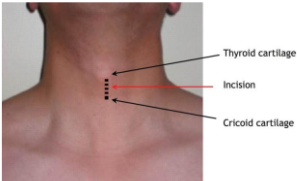
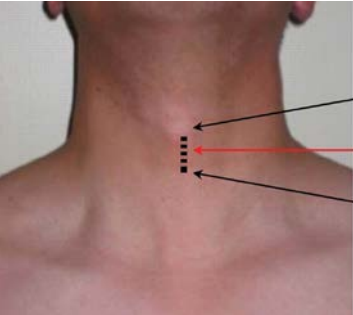

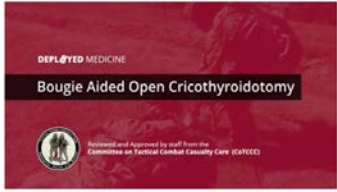
<p>14.</p>	 <p>Tactical Field Care Guidelines</p> <p>4. Airway Management (continued)</p> <p>c. Casualty with airway obstruction or impending airway obstruction:</p> <ul style="list-style-type: none"> - Allow a conscious casualty to assume any position that best protects the airway, to include sitting up - Use a chin lift or jaw thrust maneuver - Use suction if available and appropriate - Nasopharyngeal airway or - Extraglottic airway (if the casualty is unconscious) - Place an unconscious casualty in the recovery position. <p><i>* New material in red text</i></p>	<p>Tactical Field Care Guidelines</p> <p>4. Airway Management (continued)</p> <p>c. Casualty with airway obstruction or impending airway obstruction:</p> <ul style="list-style-type: none"> - Allow a conscious casualty to assume any position that best protects the airway, to include sitting up - Use a chin lift or jaw thrust maneuver - Use suction if available and appropriate - Nasopharyngeal airway or - Extraglottic airway (if the casualty is unconscious) - Place an unconscious casualty in the recovery position <p><i>* New material in red text</i></p>	<p>Read the guideline.</p>
<p>15.</p>	 <p>Maxillofacial Trauma</p>  <ul style="list-style-type: none"> • Casualties with severe facial injuries can often protect their own airway by sitting up and leaning forward. • Let them do it if they can! 	<p>Maxillofacial Trauma</p> <ul style="list-style-type: none"> • Casualties with severe facial injuries can often protect their own airway by sitting up and leaning forward. • Let them do it if they can! 	<p>It would be almost impossible to intubate a casualty with this kind of injury, especially on the battlefield at night. If his larynx and trachea are intact, he may do well. This casualty was treated with an emergency surgical airway. The only way they got this casualty to the ER alive was to let him sit up and lean forward. With an injury like this, you may have to do a surgical airway with casualty in the sitting position.</p>
<p>16.</p>	 <p>Tactical Field Care Guidelines</p> <p>Notes:</p> <p><i>* The <u>i-gel</u> is the preferred extraglottic airway because its gel-filled cuff makes it simpler to use and avoids the need for cuff inflation and monitoring. If an extraglottic airway with an air-filled cuff is used, the cuff pressure must be monitored to avoid overpressurization, especially during TACEVAC on an aircraft with the accompanying pressure changes.</i></p> <p><i>*Extraglottic airways will not be tolerated by a casualty who is not deeply unconscious. If an unconscious casualty without direct airway trauma needs an airway intervention, but does not tolerate an extraglottic airway, consider the use of a nasopharyngeal airway.</i></p> <p><i>* New material in red text</i></p>	<p>Tactical Field Care Guidelines</p> <p>Notes:</p> <p><i>* The <u>i-gel</u> is the preferred extraglottic airway because its gel-filled cuff makes it simpler to use and avoids the need for cuff inflation and monitoring. If an extraglottic airway with an air-filled cuff is used, the cuff pressure must be monitored to avoid overpressurization, especially during TACEVAC on an aircraft with the accompanying pressure changes.</i></p> <p><i>*Extraglottic airways will not be tolerated by a casualty who is not deeply unconscious. If an unconscious casualty without direct airway trauma needs an airway intervention, but does not tolerate an extraglottic airway, consider the use of a nasopharyngeal airway.</i></p>	<p>Read the guidelines.</p>






<p>17.</p>	 <p>The i-gel® Extraglottic Airway</p> 	<p>The i-gel® Extraglottic Airway</p>	<p>Click on the photo to play the video.</p>
<p>18.</p>	 <p>Tactical Field Care Guidelines</p> <p>Notes:</p> <ul style="list-style-type: none"> * For casualties with trauma to the face and mouth, or facial burns with suspected inhalation injury, nasopharyngeal airways and extraglottic airways may not suffice and a surgical cricothyroidotomy may be required. * Surgical cricothyroidotomies should not be performed on unconscious casualties who have no direct airway trauma unless use of a nasopharyngeal airway and/or an extraglottic airway have been unsuccessful in opening the airway. <p><i>* New material in red text</i></p>	<p>Tactical Field Care Guidelines</p> <p>Notes:</p> <ul style="list-style-type: none"> * For casualties with trauma to the face and mouth, or facial burns with suspected inhalation injury, nasopharyngeal airways and extraglottic airways may not suffice and a surgical cricothyroidotomy may be required. * Surgical cricothyroidotomies should not be performed on unconscious casualties who have no direct airway trauma unless use of a nasopharyngeal airway and/or an extraglottic airway have been unsuccessful in opening the airway. <p><i>* New material in red text</i></p>	<p>Read the guidelines.</p>
<p>19.</p>	 <p>Tactical Field Care Guidelines</p> <p>4. Airway Management (continued)</p> <p>c. If the previous measures are unsuccessful, perform a surgical cricothyroidotomy using one of the following:</p> <ul style="list-style-type: none"> - Cric-Key technique (preferred option) - Bougie-aided open surgical technique using a flanged and cuffed airway cannula of less than 10 mm outer diameter, 6-7 mm internal diameter, and 5-8 cm of intratracheal length - Standard open surgical technique using a flanged and cuffed airway cannula of less than 10mm outer diameter, 6-7 mm internal diameter, and 5-8 cm of intratracheal length (least desirable option) - Use lidocaine if the casualty is conscious. 	<p>Tactical Field Care Guidelines</p> <p>4. Airway Management (continued)</p> <p>c. If the previous measures are unsuccessful, perform a surgical cricothyroidotomy using one of the following:</p> <ul style="list-style-type: none"> - Cric-Key technique (preferred option) - Bougie-aided open surgical technique using a flanged and cuffed airway cannula of less than 10 mm outer diameter, 6-7 mm internal diameter, and 5-8 cm of intratracheal length - Standard open surgical technique using a flanged and cuffed airway cannula of less than 10mm outer diameter, 6-7 mm internal diameter, and 5-8 cm of intratracheal length (least desirable option) - Use lidocaine if the casualty is conscious. 	<p>Read the guideline.</p>

<p>20.</p>	 <p>Tactical Field Care Guidelines</p> <p>4. Airway Management (continued)</p> <p>e. Cervical spine stabilization is not necessary for casualties who have sustained only penetrating trauma.</p> <p>f. Monitor the hemoglobin oxygen saturation in casualties to help assess airway patency.</p> <p>g. Always remember that the casualty's airway status may change over time and requires frequent reassessment.</p> <p><i>* New material in red text</i></p>	<p>Tactical Field Care Guidelines</p> <p>4. Airway Management (continued)</p> <p>e. Cervical spine stabilization is not necessary for casualties who have sustained only penetrating trauma.</p> <p>f. Monitor the hemoglobin oxygen saturation in casualties to help assess airway patency.</p> <p>g. Always remember that the casualty's airway status may change over time and requires frequent reassessment.</p> <p><i>* New material in red text</i></p>	<p>Read the guidelines.</p>
<p>21.</p>	 <p>The Need for Cricothyroidotomy</p> <ul style="list-style-type: none"> 4,596 battlefield fatalities in Operation Iraqi Freedom and Operation Enduring Freedom combat casualties from October 2001 to June 2011 <ul style="list-style-type: none"> 87.3% of all injury mortality occurred in the prehospital environment (n = 4013) Of the prehospital deaths, 24.3% were deemed potentially survivable. (n = 976) The second most common cause (8%) of potentially preventable deaths was upper-airway obstruction due mostly to direct injury to the airway structures of the face and neck. (n = 78) <p><small>Eastbridge, et al. Death on the battlefield (2001/2011): Implications for the future of combat casualty care. J Trauma Acute Care Surg. 73, 6: Supplement 5</small></p>	<p>The Need for Cricothyroidotomy</p> <ul style="list-style-type: none"> 4,596 battlefield fatalities in Operation Iraqi Freedom and Operation Enduring Freedom combat casualties from October 2001 to June 2011 <ul style="list-style-type: none"> 87.3% of all injury mortality occurred in the prehospital environment (n = 4013) Of the prehospital deaths, 24.3% were deemed potentially survivable. (n = 976) The second most common cause (8%) of potentially preventable deaths was upper-airway obstruction due mostly to direct injury to the airway structures of the face and neck. (n = 78) 	<p>Why should medics be able to do a surgical airway on the battlefield?</p> <p>Because upper airway obstruction is the second most common cause of potentially preventable deaths on the battlefield.</p>
<p>22.</p>	 <p>Battlefield Cricothyroidotomy</p> <ul style="list-style-type: none"> "Military medics have a 33% failure rate when performing this procedure."* This is the most technically difficult procedure we ask medics, Corpsmen, and PJs to do. <p><small>* Mabey RL, Frankfurt A. An Analysis of Battlefield Cricothyroidotomy in Iraq and Afghanistan J Spec Oper Med. 2012 Spring;12(1):17-23.</small></p>	<p>Battlefield Cricothyroidotomy</p> <ul style="list-style-type: none"> Military medics have a 33% failure rate when performing this procedure. This is the most technically difficult procedure we ask medics, Corpsmen, and PJs to do. 	<p>The problem with cricothyroidotomy is that it is hard to do. Historically, combat medics have often failed to get it right on the battlefield.</p>

<p>23.</p>	 <p>Video: An Actual Cricothyroidotomy Using Standard Open Surgical Technique</p>  <p><small>Courtesy Dr. Peter Rhee, Ucin of Arizona</small></p>	<p>Video: An Actual Cricothyroidotomy Using Standard Open Surgical Technique</p>	<p>This is video of a cricothyroidotomy performed in an actual emergency situation after an attempt to intubate failed. Even in the Emergency Department cricothyroidotomy is a very difficult, time-consuming procedure.</p> <p>Click on the photo to play the video.</p>
<p>24.</p>	 <p>Preferred Surgical Airway Technique</p> <ul style="list-style-type: none"> • Cric-Key evaluation <ul style="list-style-type: none"> – Fifteen military medics with minimal training performed one Cric-Key technique and one open surgical technique on cadavers. <ul style="list-style-type: none"> • Medics were able to insert the Cric-Key in significantly less time (34 sec vs 65 sec.) • Though not statistically significant, there were three failures with the open surgical technique, and none with the Cric-Key. <p><small>Mabry, et al. A Comparison of Two Open Surgical Cricothyroidotomy Techniques by Military Medics Using a Cadaver Model. Ann Emerg Med. 2014 Jan;63(1):1-5.</small></p>	<p>Preferred Surgical Airway Technique</p> <ul style="list-style-type: none"> • Cric-Key evaluation <ul style="list-style-type: none"> – Fifteen military medics with minimal training performed one Cric-Key technique and one open surgical technique on cadavers. <ul style="list-style-type: none"> • Medics were able to insert the Cric-Key in significantly less time (34 sec vs 65 sec.) • Though not statistically significant, there were three failures with the open surgical technique, and none with the Cric-Key. 	<p>Under test conditions, medics were faster and more successful using the Cric-Key technique compared to the open surgical technique.</p>
<p>25.</p>	 <p>Cric-Key</p>  <ul style="list-style-type: none"> • The Cric-Key introducer is curvilinear, with an overall length of 19 cm, and an anteriorly directed distal tip. • Designed to guide insertion of a 5.0 cuffed Melker cricothyroidotomy airway cannula. • Combines the functions of a tracheal hook, stylet, dilator, and bougie when incorporated with the Melker airway. 	<p>Cric-Key</p> <ul style="list-style-type: none"> • The Cric-Key introducer is curvilinear, with an overall length of 19 cm, and an anteriorly directed distal tip. • Designed to guide insertion of a 5.0 cuffed Melker cricothyroidotomy airway cannula. • Combines the functions of a tracheal hook, stylet, dilator, and bougie when incorporated with the Melker airway. 	<p>As tested, the Cric-Key technique requires a scalpel, a Cric-Key introducer, a Melker airway, and a 10-cc syringe.</p>

<p>26.</p>	 <p>Cricothyroid Membrane</p>	<p>Cricothyroid Membrane</p> 	<p>Through the cricothyroid membrane is the correct path for a cricothyroidotomy. You want to make the skin incision right over this membrane. The most anterior prominence of the thyroid cartilage is the “Adam’s Apple” in men.</p>
<p>27.</p>	 <p>Surface Landmarks for Cricothyrotomy</p>	<p>Surface Landmarks for Cricothyrotomy</p> 	<p>Combat medic students should be able to demonstrate to an instructor the surface landmarks used to locate the cricothyroid membrane. These landmarks should be identified on a buddy.</p>
<p>28.</p>	 <p>Beneath the Surface Landmarks</p>	<p>Beneath the Surface Landmarks</p> <ul style="list-style-type: none"> • Hyoid Bone • Thyroid prominence (Adam’s apple) - usually visible only in males • Thyroid cartilage • Cricothyroid membrane • Cricoid cartilage • Thyroid gland 	<p>Here are the critical structures underlying the key surface landmarks.</p>

<p>29.</p>	<p>Locating the Cric Skin Incision with a Dotted Line</p>  <p>Thyroid cartilage Incision Cricoid cartilage</p> <p><small>Neckwold JC, The HC. <i>Emergency Battlefield Care</i>. Cheltenham, MA: 2006. 178-181-182</small></p> <p><small>Stevens H, Callahan J, Smith B, Kottner J. <i>Cricothyroidotomy: A Review of the Literature</i>. <i>Prehospital Emergency Care</i>. 2011;15(1):11-15.</small></p>	<p>Locating the Cric Skin Incision with a Dotted Line</p>  <p>Thyroid cartilage Incision Cricoid cartilage</p>	<p>In the practical, once the combat medic student has identified the pertinent landmarks, s/he should be required to draw a dashed vertical (mid-sagittal) line on his/her buddy's neck over the cricothyroid membrane where the incision should be made.</p>
<p>30.</p>	<p>Cricothyroidotomy Technique: CricKey</p>  <p><small>DEPLOYED MEDICINE</small> Emergency Cricothyroidotomy: Cric-Key™</p> <p><small>Reviewed and Approved by staff from the Committee on Tactical Combat Casualty Care (CTCCC)</small></p>	<p>Cricothyroidotomy Technique: CricKey</p>	<p>Click on the photo to play the video.</p>
<p>31.</p>	<p>Cricothyroidotomy Technique: Bougie</p>  <p><small>DEPLOYED MEDICINE</small> Bougie Aided Open Cricothyroidotomy</p> <p><small>Reviewed and Approved by staff from the Committee on Tactical Combat Casualty Care (CTCCC)</small></p>	<p>Cricothyroidotomy Technique: Bougie</p>	<p>Click on the photo to play the video.</p>

<p>32.</p>	 <p>Repetition and Realism in Cric Training</p>  <p>To prepare for scenarios like this one, combat medics should perform cricothyrotomy at least five times during training on an anatomically realistic model.</p>	<p>Repetition and Realism in Cric Training</p> <p>To prepare for scenarios like this one, combat medics should perform cricothyrotomy at least five times during training on an anatomically realistic model.</p>	<p>Cricothyrotomy is a difficult procedure even under the best of circumstances. Under stress, the combat medic will fall back on his training. Repetition and realism (both clinical and tactical) during training enhances skill development and knowledge retention in combat trauma care. Cricothyrotomy is a critical skill that should be practiced repeatedly on a realistic model.</p>
<p>33.</p>		<p>Questions?</p>	
<p>34.</p>	 <p>Airway Practical</p> <ol style="list-style-type: none"> 1. Identify the cricothyroid membrane <i>-Use a skin marker to mark site</i> 2. Nasopharyngeal Airway 3. i-gel 4. Surgical Airway <i>- 5 reps per student</i> 	<p>Airway Practical</p> <ol style="list-style-type: none"> 1. Identify the cricothyroid membrane - Use a skin marker to mark site 2. Nasopharyngeal Airway 3. i-gel 4. Surgical Airway - 5 reps per student 	<p>Nasopharyngeal airway skill sheet i-gel skill sheet Cric-Key skill sheet</p>